

# RIGHT HEART MORPHOLOGY AND FUNCTION IN PEDIATRIC HEART TRANSPLANTATION RECIPIENTS

R. Gravino<sup>1</sup>; R. Vastarella<sup>1</sup>; L. Baldini<sup>1</sup>; G. Limongelli<sup>1</sup>; A. Petraio<sup>2</sup>;  
G. Salerno<sup>1</sup>; A. Rea<sup>1</sup>; C. Amarelli<sup>2</sup>; C. Maiello<sup>1</sup>; M.G. Russo<sup>1</sup>; G. Pacileo<sup>1</sup>

1. Heart Failure Unit, AORN dei Colli - Monaldi Hospital, Naples  
2. Heart TRansplant Unit, AORN dei Colli - Monaldi Hospital, Naples

## BACKGROUND

The right heart is a major determinant of prognosis in cardiac transplant recipient patients.

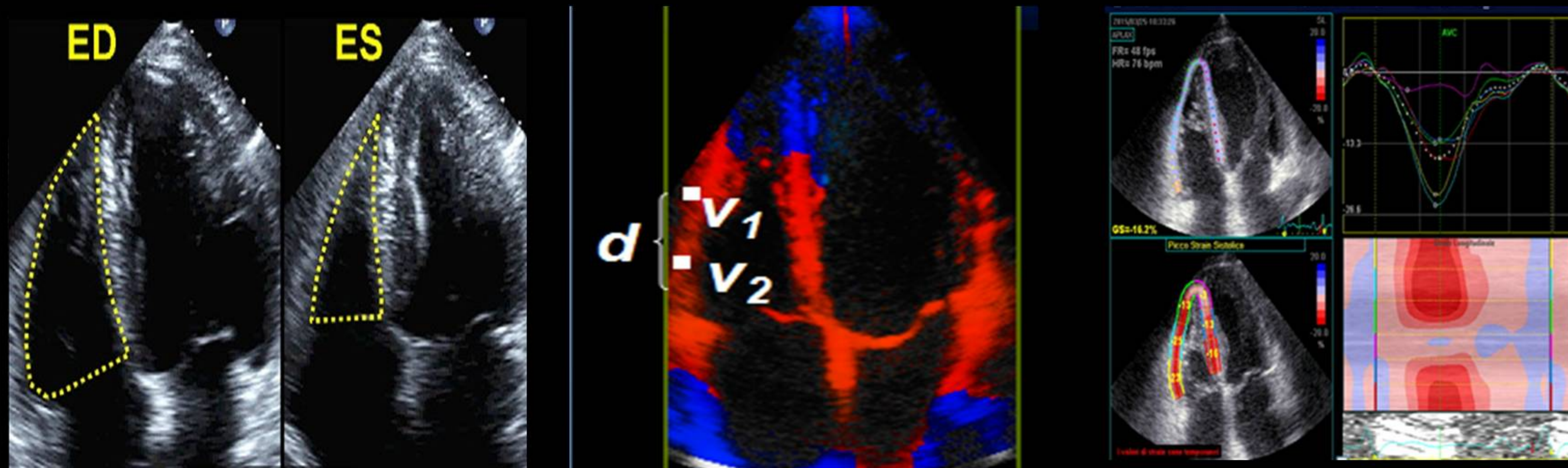
## AIM

To investigate right ventricular morphology and function in pediatric cardiac transplant recipient patients using standard transthoracic echocardiography and a new echocardiographic software like bidimensional strain (2D-strain), adapted for right ventricular analysis.

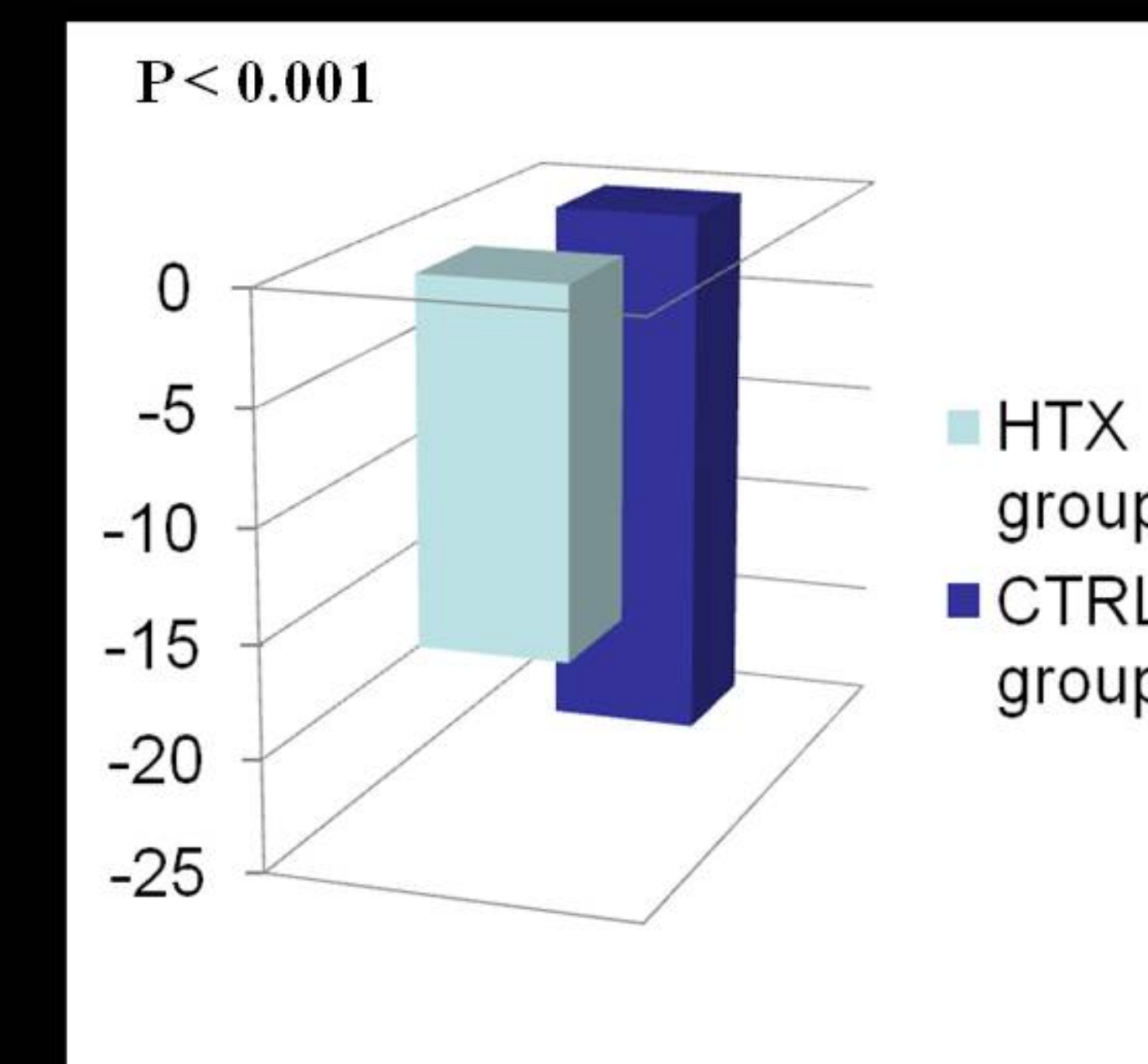
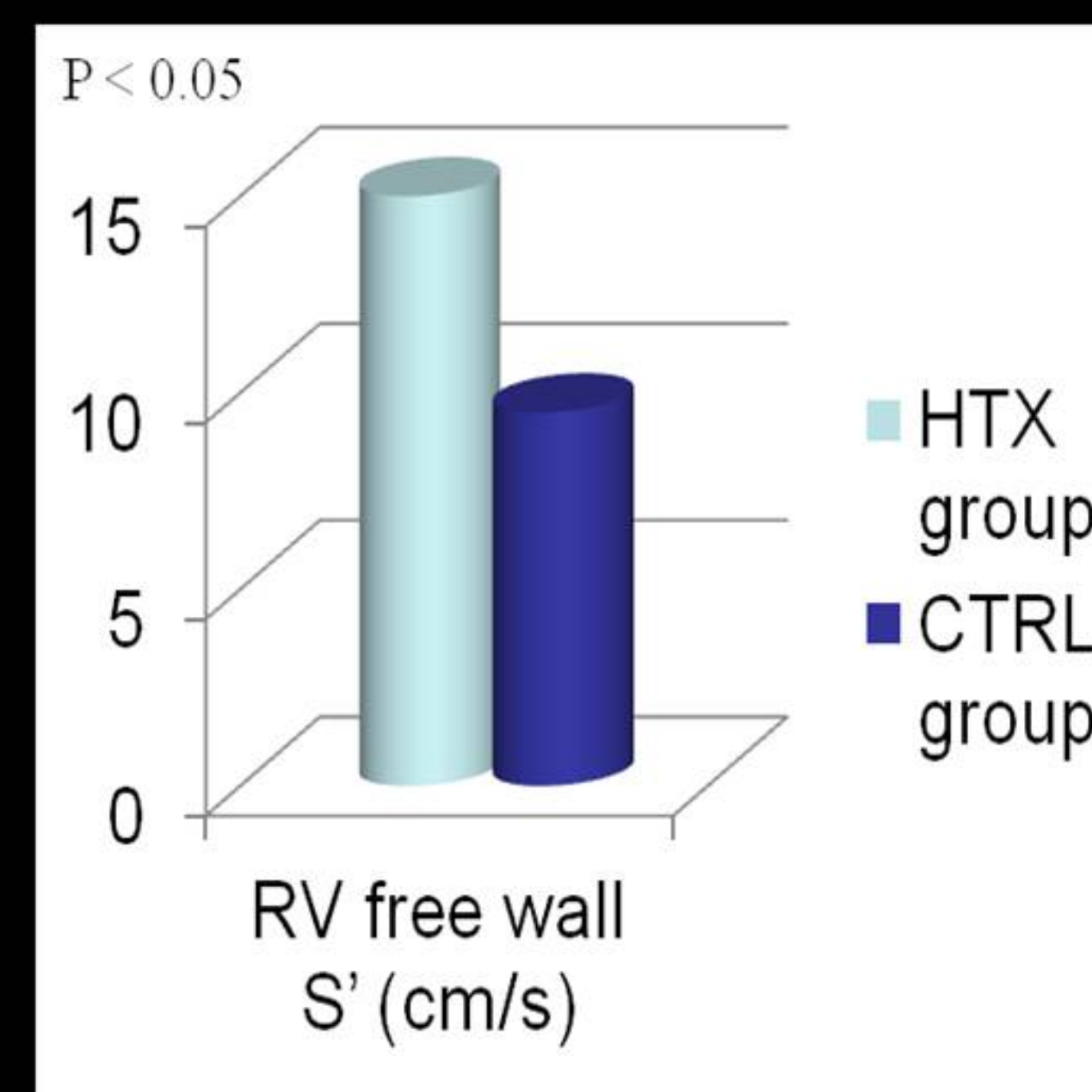
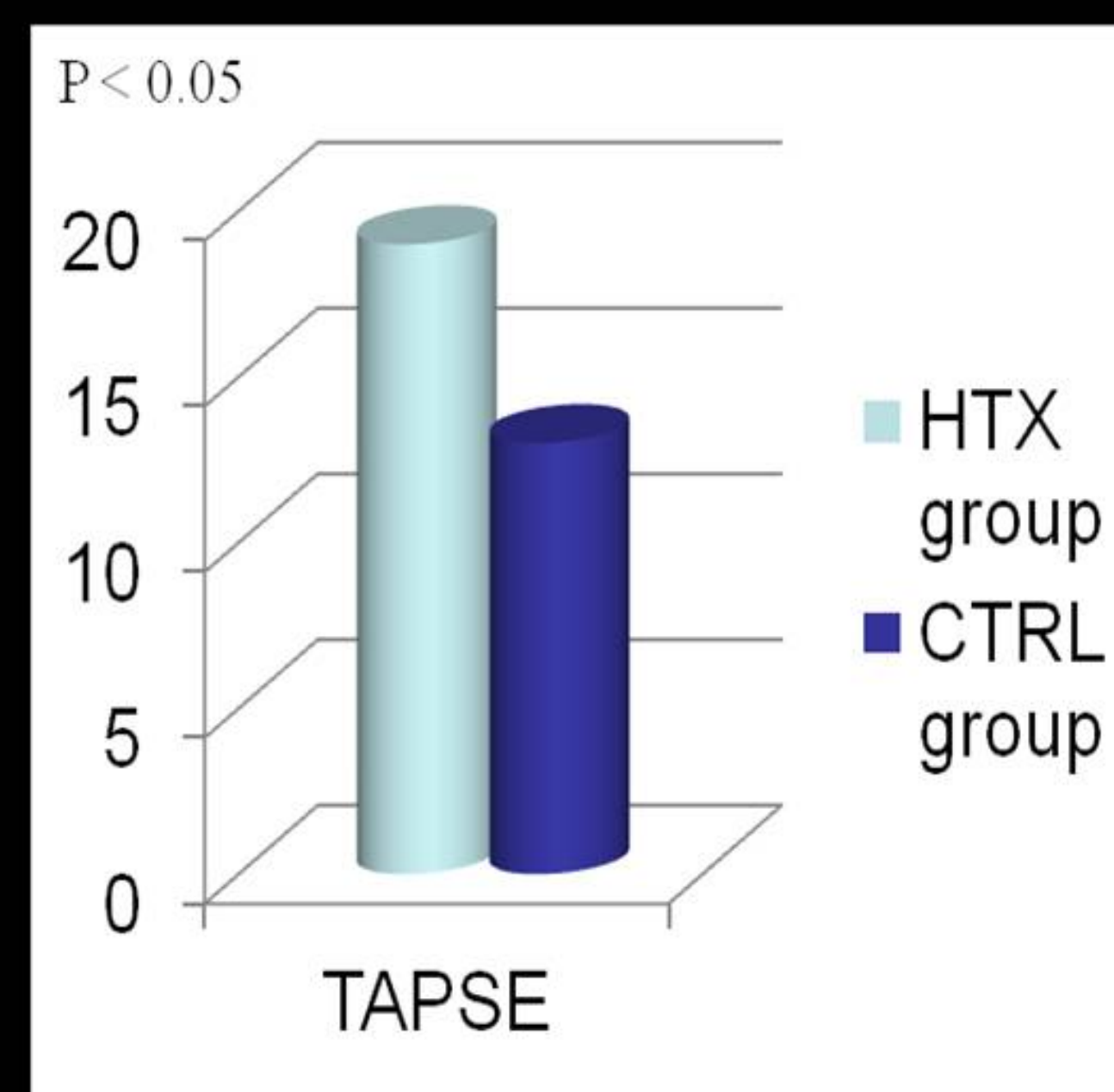
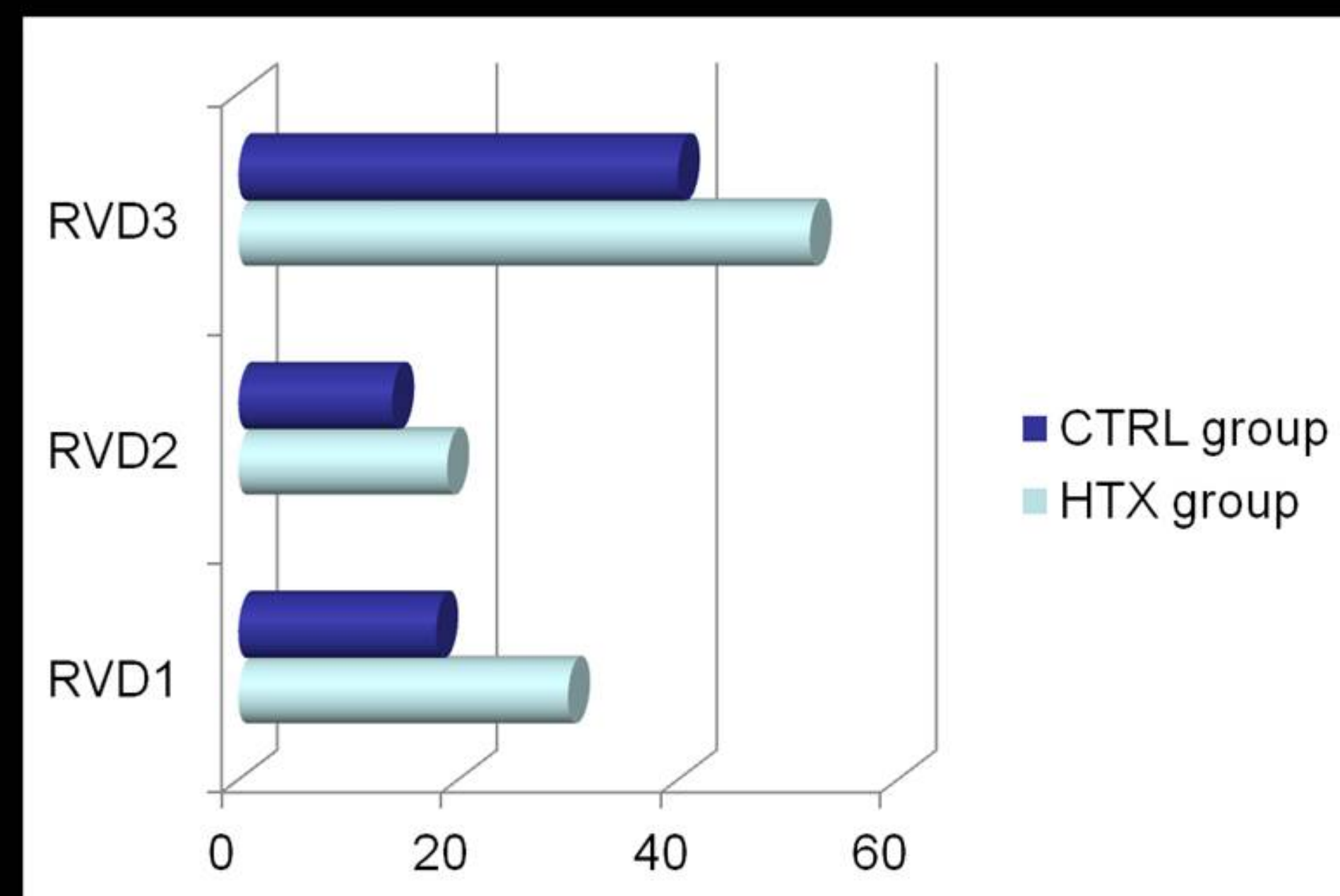
## Study population

20 relatively stable pediatric cardiac transplant recipient patients (11 men;  $14.5 \pm 4.5$  years;  $3.8 \pm 3$  years after transplantation) and 40 healthy age-comparable and sex-comparable controls

## Methods



## RESULTS



## CONCLUSIONS

In our study we observed that the pediatric population that underwent cardiac transplantation shows a reduction of right ventricular performance along the long axis suggested by TAPSE, right ventricular Sm and global bidimensional strain. Further studies with larger populations are needed to confirm these data, to examine in more detail geometrical rather than functional changes of the right ventricle in these patients and to define the role of new echocardiographic technologies in their clinical management.